



PRESENTING CLINICAL SIGNS

History: Murmur first detected 2.5 years ago. Presented in September for coughing when excited. Last night, cough worsened. Radiographs showed LAE. Cough improved with furosemide, pimobendan, and O2.

DATE

2/9/23

ECHOCARDIOGRAPHIC FINDINGS

2D, M-mode, and Doppler study.

PERFORMED BY:

Kelly Vazquez

INTERPRETED BY

Keith Blass, DVM,
MS, DACVIM
(Cardiology)

There is moderate to severe left atrial dilation. The mitral valve leaflets are thickened and exhibit mild systolic prolapse. There is Doppler evidence of mitral regurgitation present. There is mild left ventricular dilation. Left ventricular systolic function is hyperdynamic. The aorta and aortic valve are normal. Right atrial and right ventricular dimensions are normal. The tricuspid valve is normal. The pulmonary artery and pulmonic valve are normal. No pericardial effusion or cardiac masses are seen.

LA - 34.2 mm
LVIDd - 26.7 mm
LVIDs - 10.8 mm
FS - 59.6%
RA - 16.2 mm
LVOT - 1.05 m/s
RVOT - 0.57 m/s

PATIENT

Milo Comerfurl

SPECIES ASSESSMENT/RECOMMENDATIONS

Degenerative mitral valve disease

Canine

This examination demonstrates regurgitation of blood across Milo's mitral valve resulting from degenerative valve disease. Secondary to his regurgitation, Milo has moderate to severe dilation of his left atrium and mild dilation of his left ventricle, though his left ventricular systolic function is well-preserved. Given the presence of moderate to severe left atrial dilation, it's very likely that Milo's mitral valve disease is the cause of the acute worsening of his cough, and his disease puts him at risk for the development of exercise intolerance, syncope, and labored breathing.

BREED

Shih Tzu

SEX

Recommended maintenance therapy based on this exam includes furosemide (1-2 mg/kg BID), enalapril (2.5 mg BID), and pimobendan (1.25 mg BID).

MN

A renal/electrolyte profile is recommended in 1-2 weeks. A recheck echocardiogram is recommended in 6-9 months. Repeat radiographs are recommended if Milo experiences labored breathing.

AGE

5 y

WEIGHT

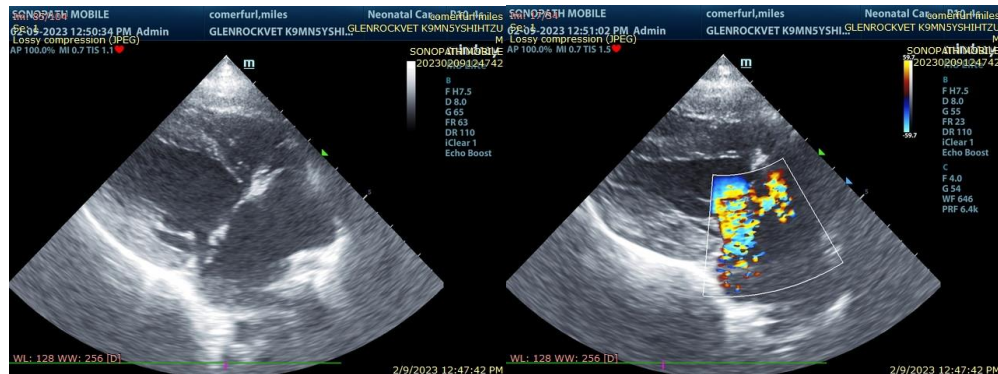
10 lb

HOSPITAL NAME

Glen Rock VH

REFERRING VET

Dr. Stekler





DATE

2/9/23

The information and recommendations provided are based on the images presented by the referring veterinarian. No evaluation can be communicated regarding pathology that was not visible in the image/video clips provided.

PERFORMED BY:

Kelly Vazquez

Thank you for this referral. If the clinical or image interpretation does not parallel your findings or if I can be of any further assistance please contact me.

INTERPRETED BY

Keith Blass, DVM,
MS, DACVIM
(Cardiology)

Keith Blass, DVM, MS, DACVIM (Cardiology)
KeithBlass@gmail.com
631-804-5754

PATIENT

Milo Comerfurl

SPECIES

Canine

BREED

Shih Tzu

SEX

MN

AGE

5 y

WEIGHT

10 lb

HOSPITAL NAME

Glen Rock VH

REFERRING VET

Dr. Stekler